CT Angiography for Pulmonary Embolism diagnosis during pregnancy and post-partum

Marie-Pierre REVEL- Pompidou Hospital,
Paris Descartes University, Paris. France.

During pregnancy and post-partum

- **Risk for venous thrombo-embolism increased by a factor of four**
  - **Heit, Ann Intern Med, 2005**
- **PE leading cause of maternal death in developed countries**
  - **Horlander, Arch Intern Med, 2003**

What diagnostic algorithm?

- **Evaluating the clinical probability is not possible**
  - No specific score for pregnant/post-partum patients
- **D-dimers are often elevated**
  - Even normal D-dimers exclude PE only if clinical probability not high, which cannot be assessed

↓

Systematic investigation required
PE Prevalence usually low (3.6% Shahir, AJR 2010)

↓

Check for obvious alternative diagnosis
CHEST RADIOGRAPHY

Peripartum cardiomyopathy: a comprehensive review.
Abboud J et al 17. Review -Int J Cardiol. 2007 Jun 12;118(3):295-303

What diagnostic algorithm?

- **Lower limb ultrasonography**
  - Not consensual
  - STR/ATS Recommendation (RSNA 2010): only if symptoms of DVT
- **Then Lung Scintigraphy (LS) or CTA?**
  - **Still debated**

Learning objectives

- To review the role of CTA for PE diagnosis during pregnancy and post-partum
  - LS /CTA pros and cons
- To explain how to optimize CTA protocols
  - Low rate of non-diagnostic results
  - Low radiation dose
- To review key imaging findings

Learning objectives

- **To review the role of CTA for PE diagnosis during pregnancy and post-partum**
  - **LS /CTA pros and cons**
- To explain how to optimize CTA protocols
  - Low rate of non-diagnostic result
  - Radiation dose optimization
- To review key imaging findings

LS/CTA during pregnancy

- **Fetal radiation dose**
  - A little higher with LS
    - During the first and second trimester
    - MonteCarlo simulation

      (Winer-Muram, Radiology 2002)
  - Quite negligible with both techniques

LS/CTA pros √ and cons ×

- **Lung Scintigraphy**
  - × Not always available
  - ✓ Breast radiation dose<<< CTA
  - ✓ **Inconclusive results < general population**
- **CTA**
  - × Iodinated contrast medium: fetal thyroid dysfunction?
  - ✓ Allows alternative diagnosis
  - × **Inconclusive results > general population**

LS/CTA pros √ and cons ×

- **Lung Scintigraphy**
  - × Not always available
  - ✓ Breast radiation dose<<< CTA
  - ✓ **Inconclusive results < general population**
- **CTA**
  - × Iodinated contrast medium: fetal thyroid dysfunction?
  - ✓ Allows alternative diagnosis
  - × **Inconclusive results > general population**

LS/CTA pros √ and cons ×

- **Lung Scintigraphy**
  - × Not always available
  - ✓ Breast radiation dose<<< CTA
  - ✓ **Inconclusive results < general population**
- **CTA**
  - × Iodinated contrast medium: fetal thyroid dysfunction?
  - ✓ Allows alternative diagnosis
  - × **Inconclusive results > general population**

Fetal thyroid dysfunction

- **No risk before 16 weeks' gestation**
- **Hypothyroidism reported with Amiodarone**
  - Lomenick et al J Perinatol 2004
- **Not with iodinated contrast injection**
  - Bourjeily et al. Radiology 2010: ***« Neonatal thyroid function: effect of a single exposure to iodinated contrast medium in utero »***
    - 334 newborns, all had normal T4 level at birth

LS/CTA pros √ and cons ×

- **Lung Scintigraphy**
  - × Not always available
  - ✓ Breast radiation dose<<< CTA
  - ✓ **Inconclusive results < general population**
- **CTA**
  - × Iodinated contrast medium: fetal thyroid dysfunction?
  - ✓ Allows alternative diagnosis
  - × **Inconclusive results > general population**

Mycoplasma pneumoniae infection@25 weeks'gestation

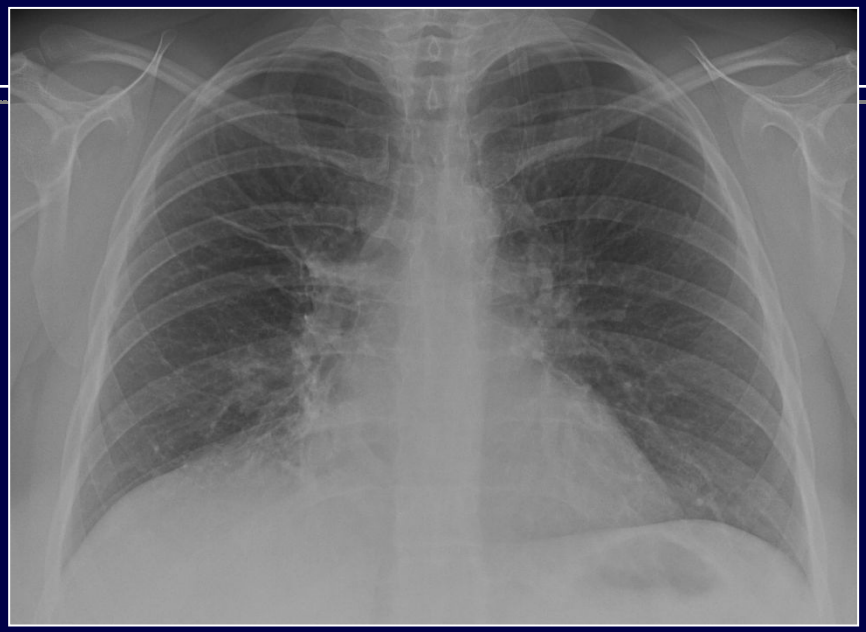

Chest pain 6 days after vaginal delivery

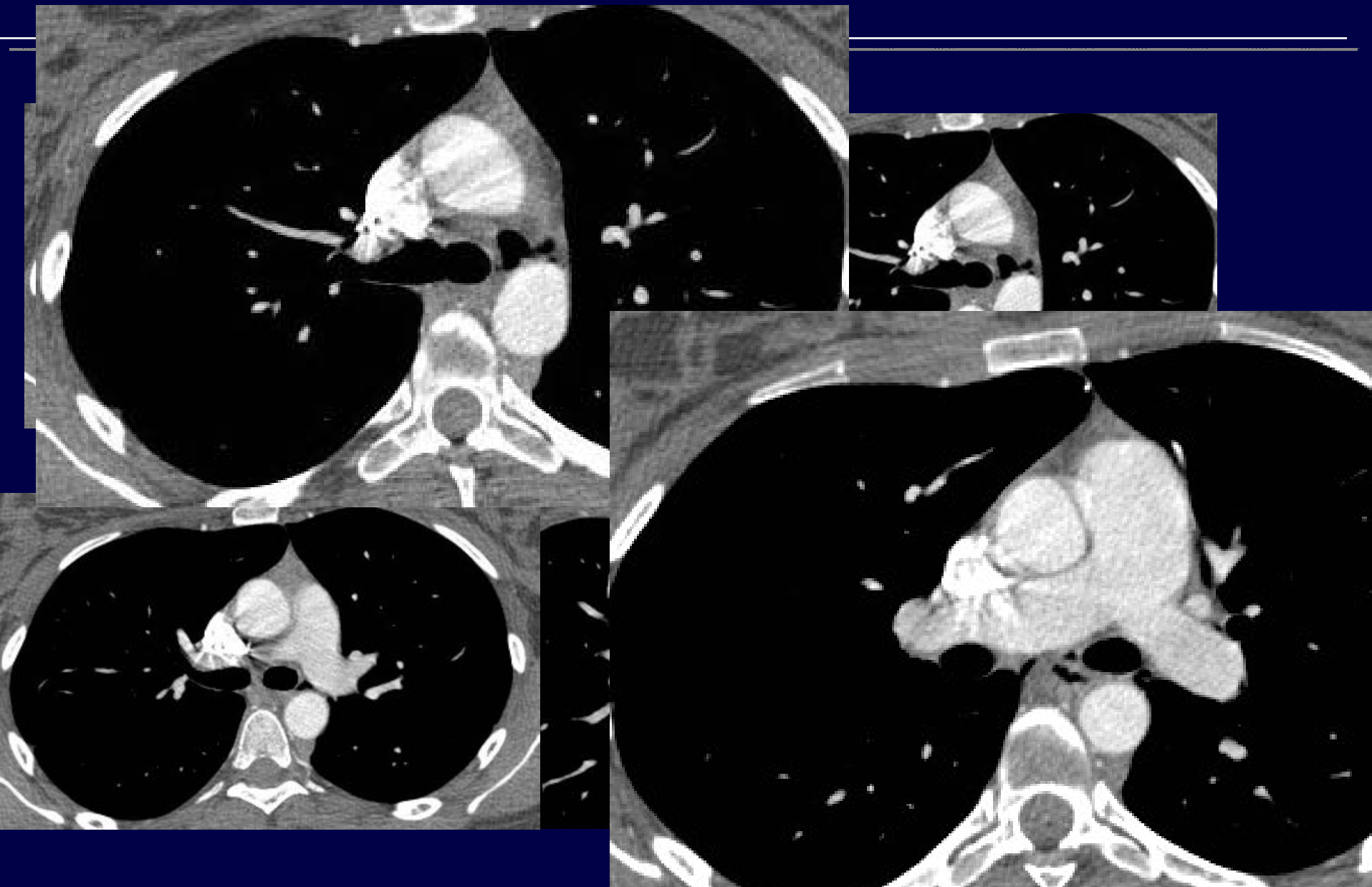

Hamman's syndrome

Postpartum pneumomediastinum- 1 in 100 000 deliveries

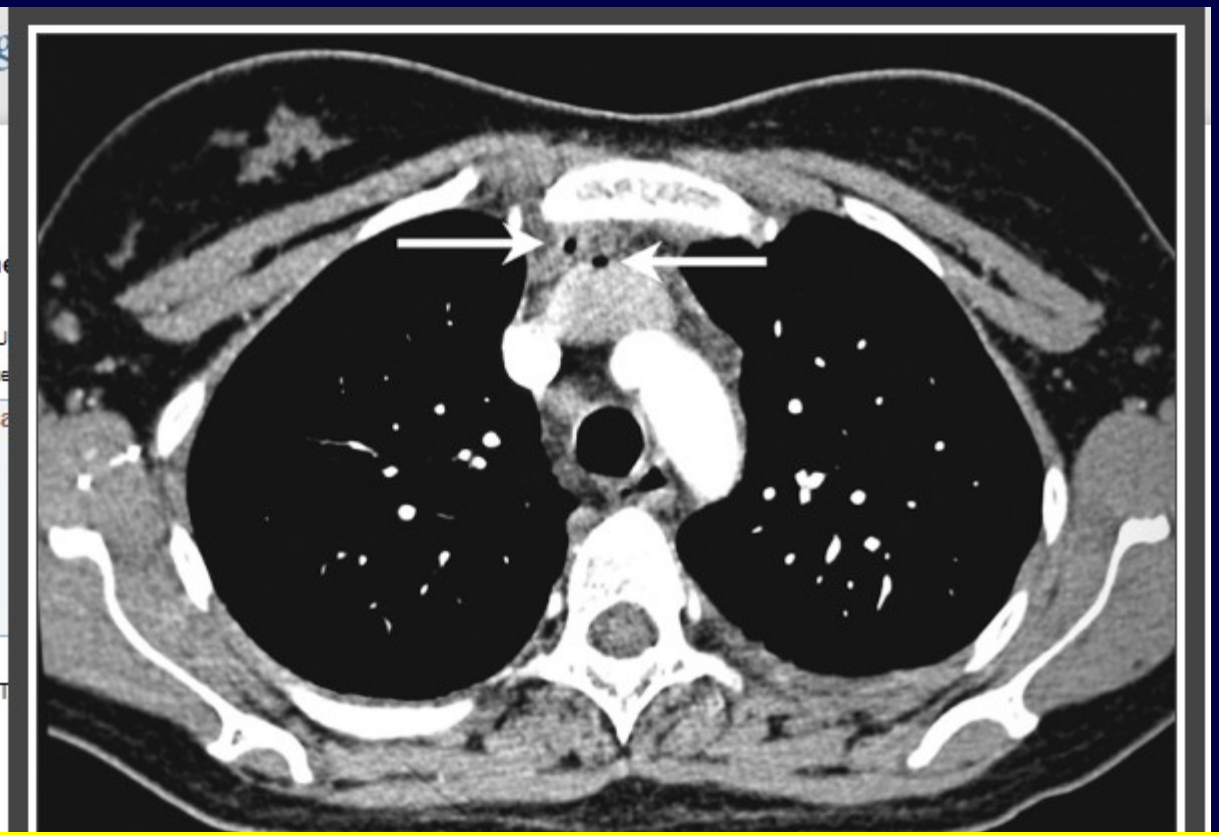

Log in / create accou

Article Discussion Read View source View history Search

WIKIPEDIA
The Free Encyclopedia

Main page
Contents
Featured content
Current events
Random article
Donate to Wikipedia

Louis Hamman

From Wikipedia, the free encyclopedia

Louis Virgil Hamman, M.D. (December 20, 18

He was graduated M.D. from Johns Hopkins and
Tuberculosis Clinic.

He said: "The physician, consciously or otherwis

Conditions which carry his name: Hamman's sig

louis hamman

Environ 22 500 résultats (0,35 secondes)

d of the new Phipps

lung expert **Louis Hamman**.
230 × 239 - 10 ko - jpg
esgweb1.nts.jhu.edu



Louis Hamman | TripAtlas.com
480 × 360 - 23 ko - jpg
tripatlas.com

Louis Hamman | Ask.com Encyclopedia

Louis Hamman | Ask.com Encyclopedia

LS/CTA pros √ and cons ×

- **Lung Scintigraphy**
  - × Not always available
  - ✓ Breast radiation dose<<< CTA
  - ✓ **Inconclusive results < general population**
- **CTA**
  - × Iodinated contrast medium: fetal thyroid dysfunction?
  - ✓ Allows alternative diagnosis
  - × **Inconclusive results > general population**

Higher rate of inconclusive CTA

General Population	Pregnancy		Post-partum
5 to 10%	Cahill et al -Obstet Gynecol 2009	17%	Revel et al- JTH 2008
	U-Kim-Im et al - Eur Radiol 2008	27.5%	20%
	Ridge et al - AJR 2009	32%	

- **Poor opacification**
  - **Increased blood volume**

    +50% @ 36 weeks, return to normal 6 month post-partum
  - **Increased pulsatility, poor mixing**

Poor opacification: risk of false negative

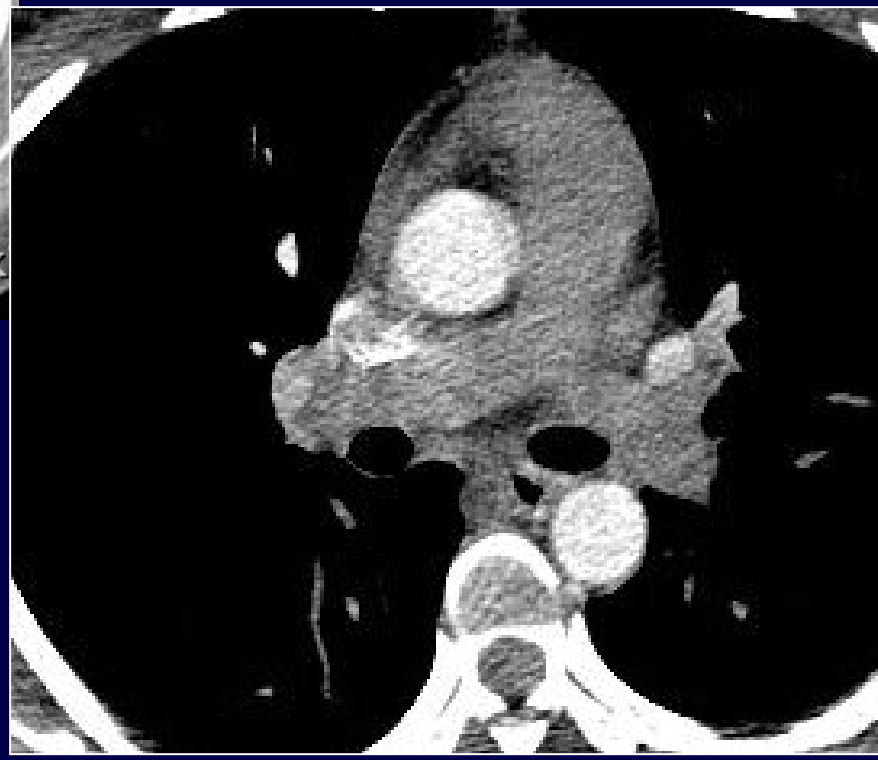

Poor opacification: risk of false positive

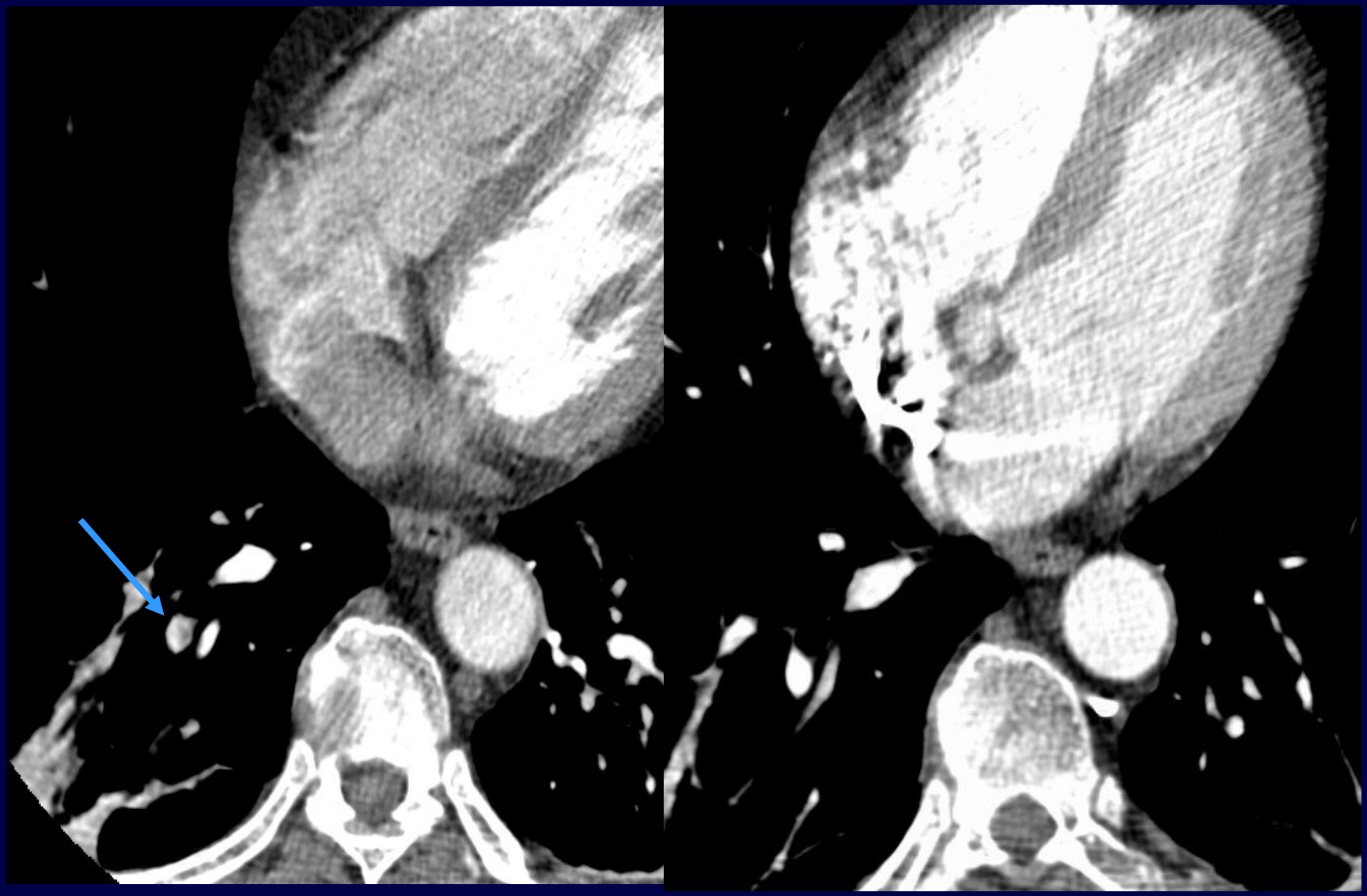

Learning objectives

- To review the role of CTA for PE diagnosis during pregnancy and post-partum
  - LS /CTA pros and cons
- **To explain how to optimize CTA protocols**
  - **Low rate of non-diagnostic result**
  - **Low radiation dose**
- To review key imaging findings

How to perform CTA?

Two crucial objectives

1- Low rate of non-diagnostic results

Optimizing opacification

2- Low radiation dose

Low breast radiation dose

Optimizing opacification

≈ **Three RULES**

1. Use sufficient amount of contrast
2. Avoid deep inspiration
3. Do not start acquisition immediately after apnea

Optimizing opacification

1. Use sufficient amount of contrast

- At least 100 cc
- Increased blood volume during pregnancy and post–partum
- Ridge et al. 32% inconclusive CTA results only 75 cc

Optimizing opacification

2.Avoid deep inspiration

Increases Inferior Caval blood flow (non-opacified blood)

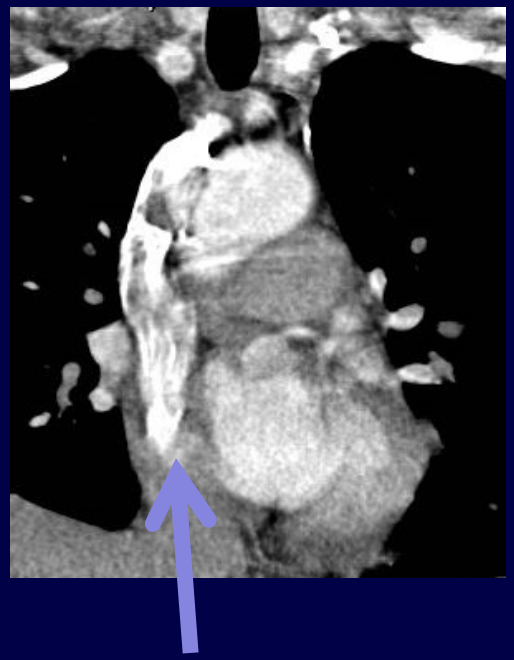

Inferior caval blood flow affects the quality of CTPA during pregnancy- Karabulut. Eur Radiol 2009

Deep inspiration

Shallow breathing

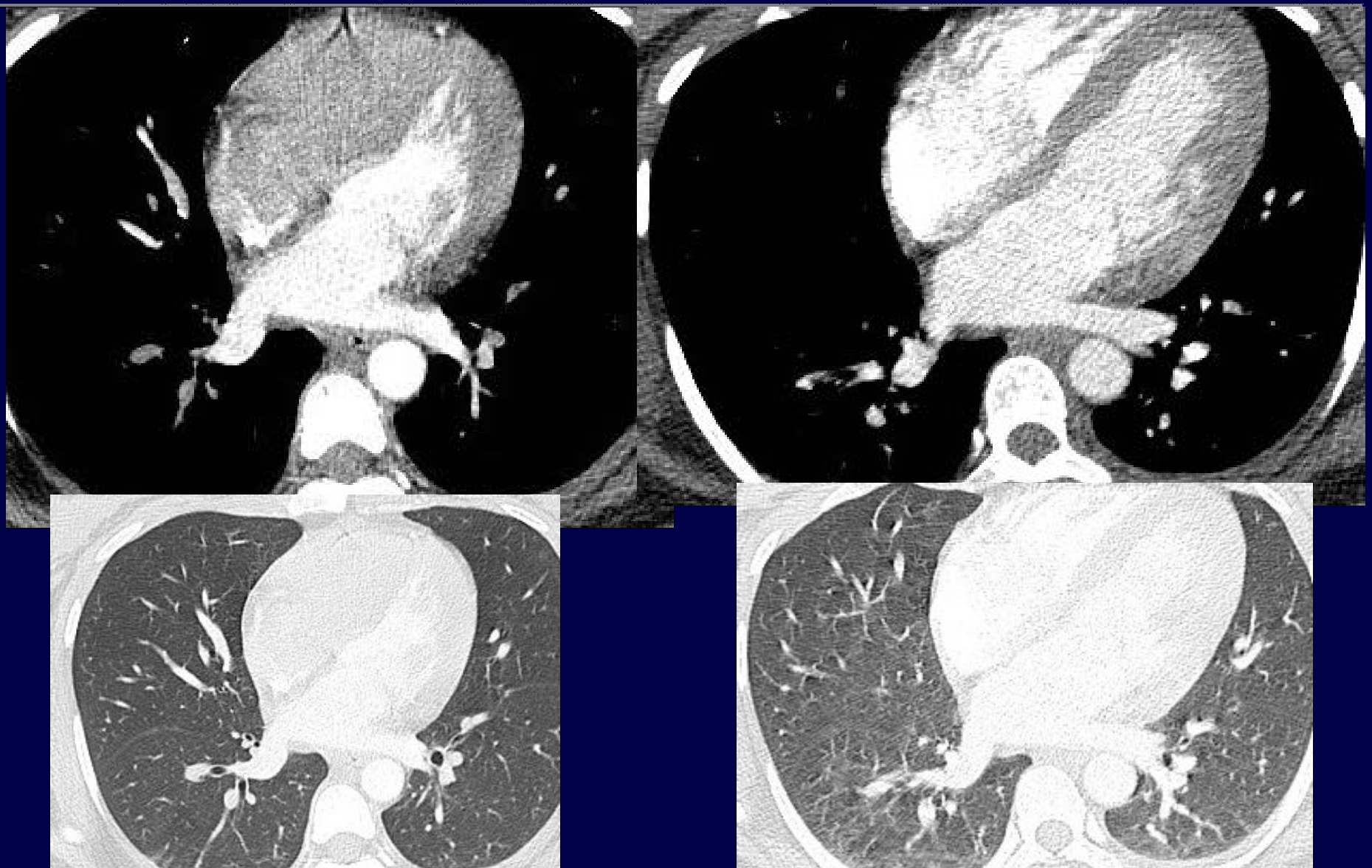

Optimizing opacification

3. To not start acquisition immediately after apnea

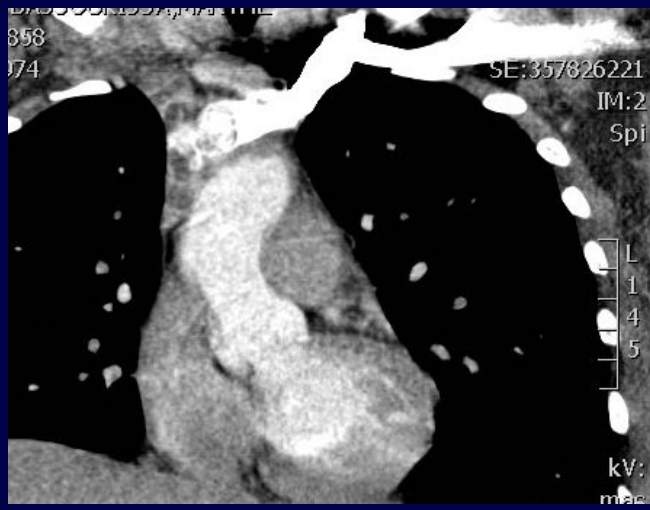

Transient decrease of superior caval blood flow (opacified blood)

Optimizing opacification

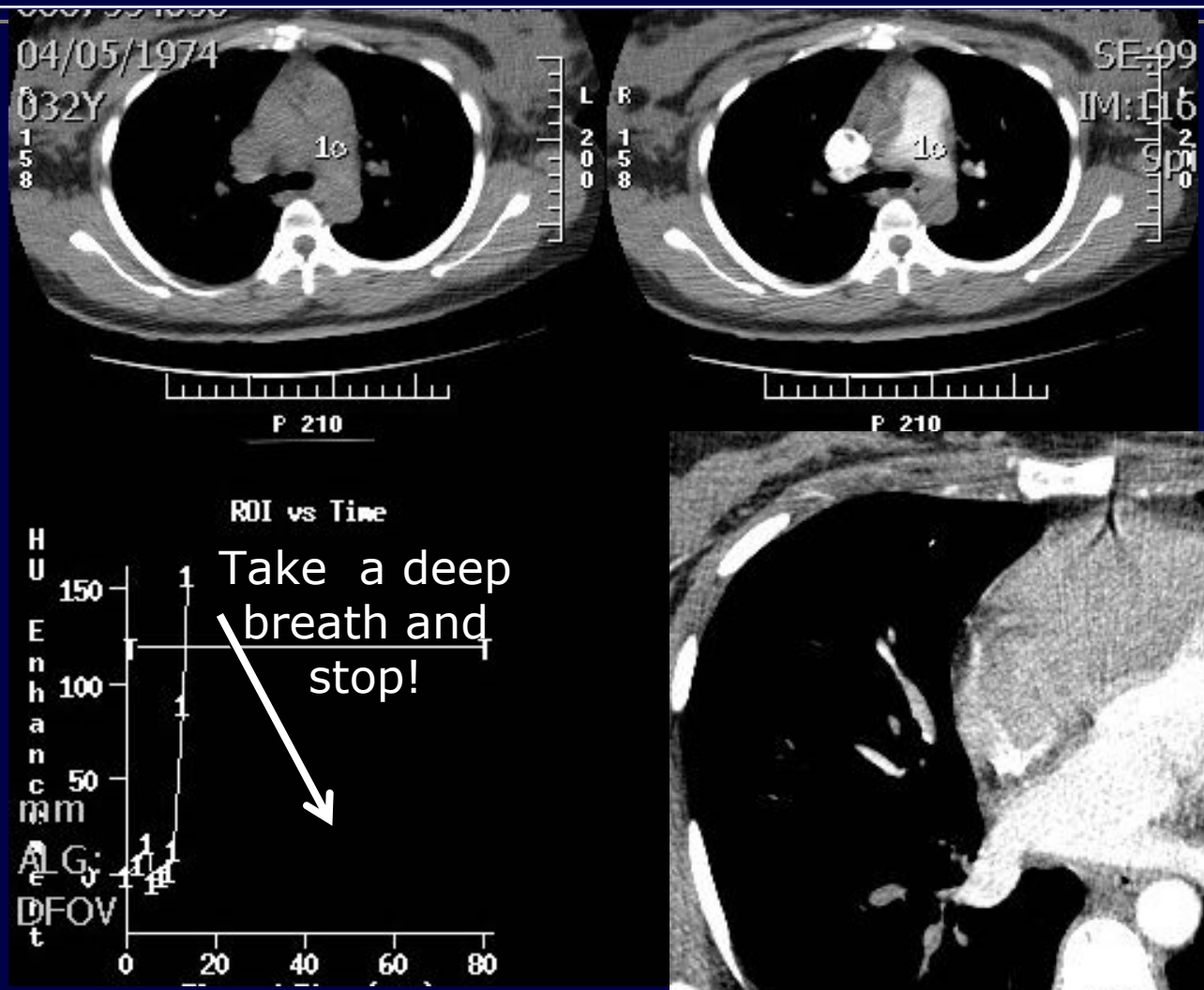

Optimizing opacification

- Avoid deep breath, sufficient amount and rate, start @18-25 s rather than bolus triggering

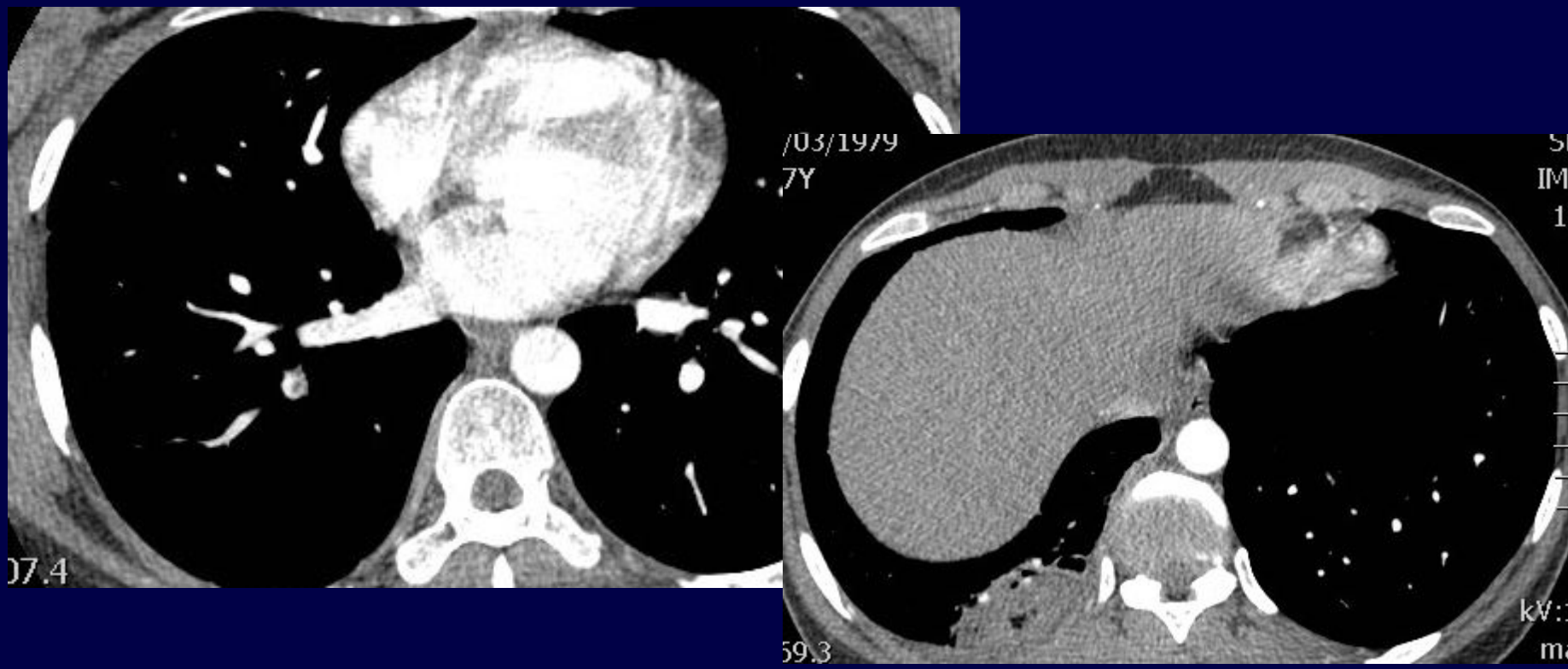

Radiation dose optimization

- Acquisition parameters
- Shielding
  - Bismuth shielding
  - Lead shielding

Acquisition parameters

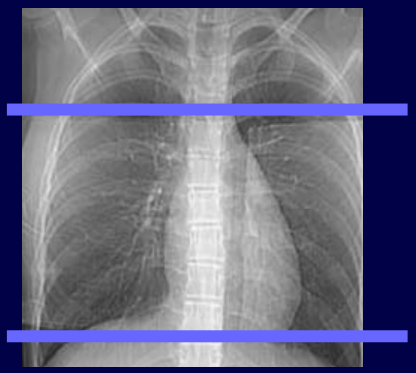

- Limitation in Z axis
- Pitch, mA, kV, rotation time
  - **Adaptation of parameters depends on CT unit manufacturer**
    - Siemens: radiation dose is not lower with higher pitch
    - GE: dose modulation: requires increasing noise index
  - **Check estimated DLP**

- Litmanovich et al JACT 2009 (Reduction in Z axis, 200 mA, 100kV)

mean effective dose: 5.21±1.54 mGy

Bismuth SHIELDING

- Used for pediatrics (Fricke et al AJR 2003)

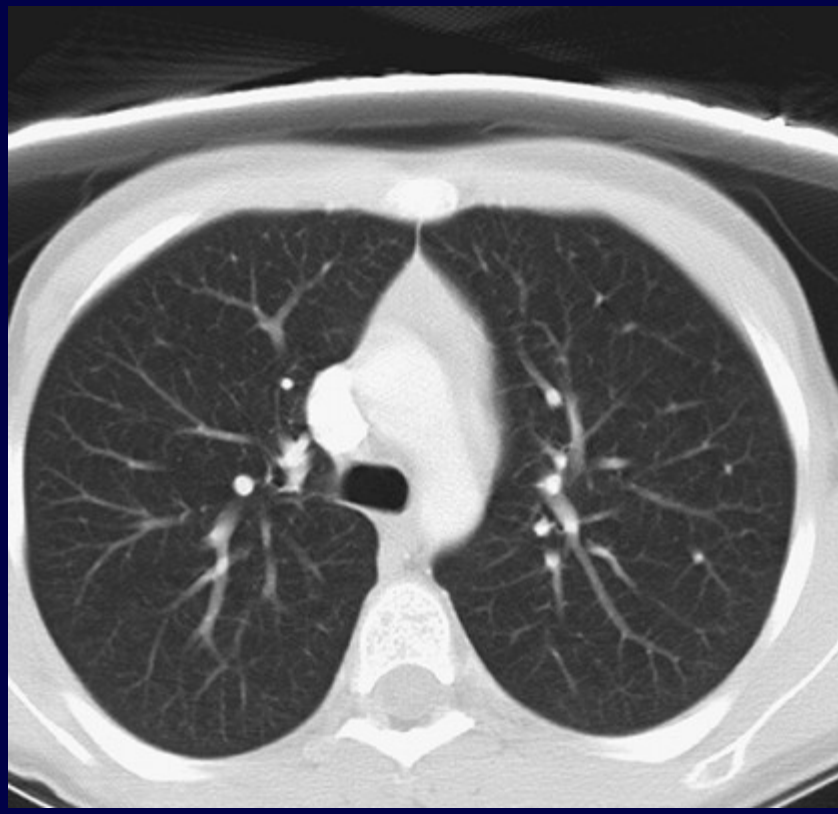

Bismuth SHIELDING

- For adults
  - Controversial data
    - Hurwitz et al AJR 2009: 55% dose reduction without quality loss
    - Yilmaz JCT 2007: 40% dose reduction without quality loss
    - Vollmar et al Eur Radiol 2008: 50% dose reduction with noise increase (+ 40%) and artefacts

- Alternative: **Organ-based Angular Tube Current Modulation**
  - **Flohr T. rsna 2006: 30 to 40% breast dose reduction**
  - **Wang et al RSNA 2010: > breast shielding**

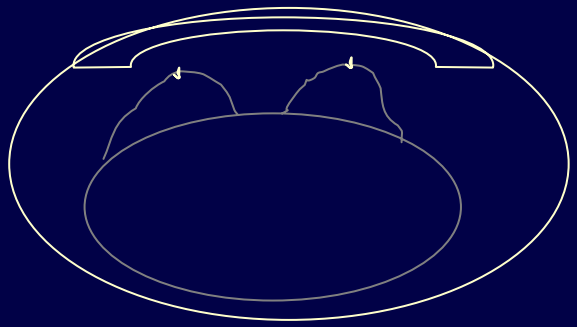

Lead shielding

- For fetal dose reduction (negligible)
- **Does not stop trans- diaphragmatic diffusion**
  - Barium ingestion…
- Efficient
  - Kennedy et al. Br J Radiol 2007
  - Doshi et al Br J Radiol 2008 : 35% dose reduction
- **After the scout view!!!**

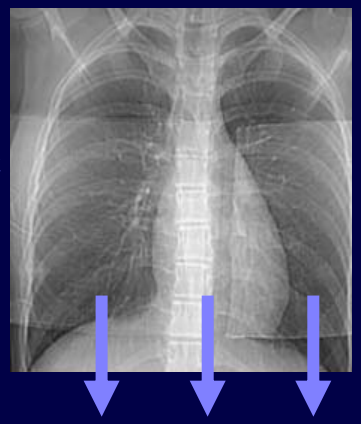

LS/CTA during pregnancy

- LS: Recommended if chest radiography is normal (CAHILL et al Obstet Gynecol. 2009)
  - And no history of asthma, no alternative diagnosis suspected, available
- CTA: Recommended by the Fleishner society after negative US

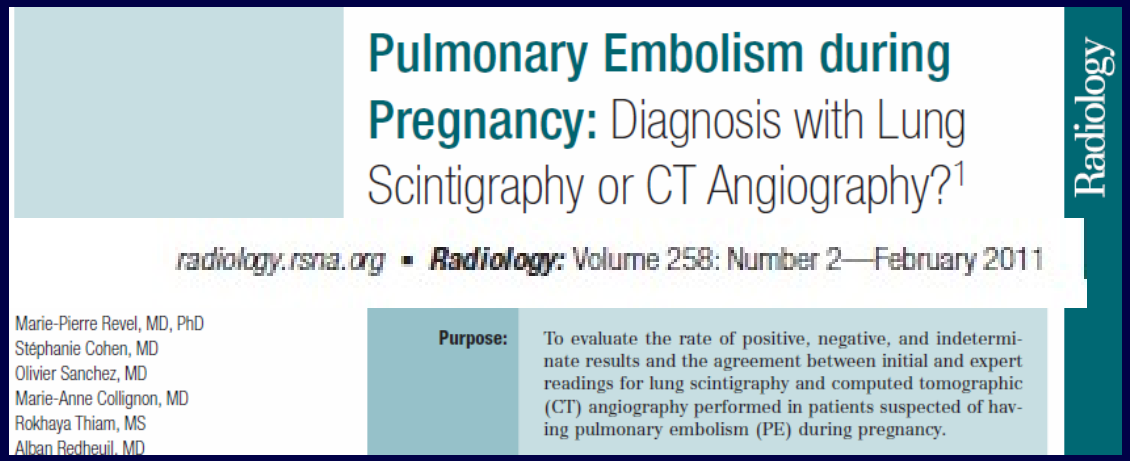

Pulmonary Embolism during Pregnancy: Diagnosis with Lung Scintigraphy or CT Angiography?[1]

Radiology

radiology.rsna.org • Radiology: Volume 258: Number 2—February 2011

Marie-Pierre Revel, MD, PhD
Stéphanie Cohen, MD
Olivier Sanchez, MD
Marie-Anne Collignon, MD
Rokhaya Thiam, MS
Alban Redheuil, MD

Purpose: To evaluate the rate of positive, negative, and indeterminate results and the agreement between initial and expert readings for lung scintigraphy and computed tomographic (CT) angiography performed in patients suspected of having pulmonary embolism (PE) during pregnancy.

128 patients, @22weeks' GA, 43 CTA & 94 LS

Results

Result	CTA	LS	p
+	**16 %** (7/43)	**11 %** (10/94)	0.35
-	**65 %** (28/43)	**68 %** (64/94)	0.73
?	**19 %** (8/43)	**21 %** (20/94)	0.72
Need for other test	**5 %** (2/43)	**7 %** (7/94)	0.42
Alternative Diagnosis	28% (12/43)	0%	
Kappa value	0.84 (0.68- 0.99)	0.75 (0.63- 0.87)	

LS/CTA during pregnancy

- **Similar performance**
- **Scintigraphy**
  - **Lower breast radiation dose**
- **CTA** (more available in emergency)
  - **Better agreement**
  - **Allows alternative diagnosis**

Shahir et al- AJR 2010: *The choice of study should be based on other considerations, such as radiation concern, radiographic results, alternative diagnosis, and equipment availability. Reducing the amount of radiation to the maternal breast favors use of perfusion scanning when the radiographic findings are normal and there is no clinical suspicion of an alternative diagnosis.*

Post-partum

- **Same problems**
  - Same hemodynamic changes
  - Same technique, plus **CT venography**
  - Increased detection of VTE and alternative diagnosis:
  - **Direct impact on clinical management in 18% of the patients**

Journal of Thrombosis and Haemostasis, **6**: 1478–1481 DOI: 10.1111/j.1538-7836.2008.03078.x

ORIGINAL ARTICLE

Contribution of indirect computed tomographic venography to the diagnosis of postpartum venous thromboembolism

M. P. REVEL,* O. SANCHEZ,† S. DECHOUX,* S. COUCHON,* G. FRIJA,* J. CAZEJUST,* G. CHATELLIER‡ and G. MEYER†

*Radiology Department, Hopital Europeen Georges Pompidou, APHP, Faculte de Medicine, Universite Paris Descartes, Paris; †Division of Respiratory and Intensive Care Medicine, Hopital Europeen Georges Pompidou, APHP, Faculte de Medicine, Universite Paris Descartes, Paris; and ‡Clinical Research Department, Hopital Europeen Georges Pompidou, APHP, Faculte de Medicine, Universite Paris Descartes, Paris, France

Post-partum

- Increased VTE detection rate
- Diagnosis of ovarian vein thrombosis

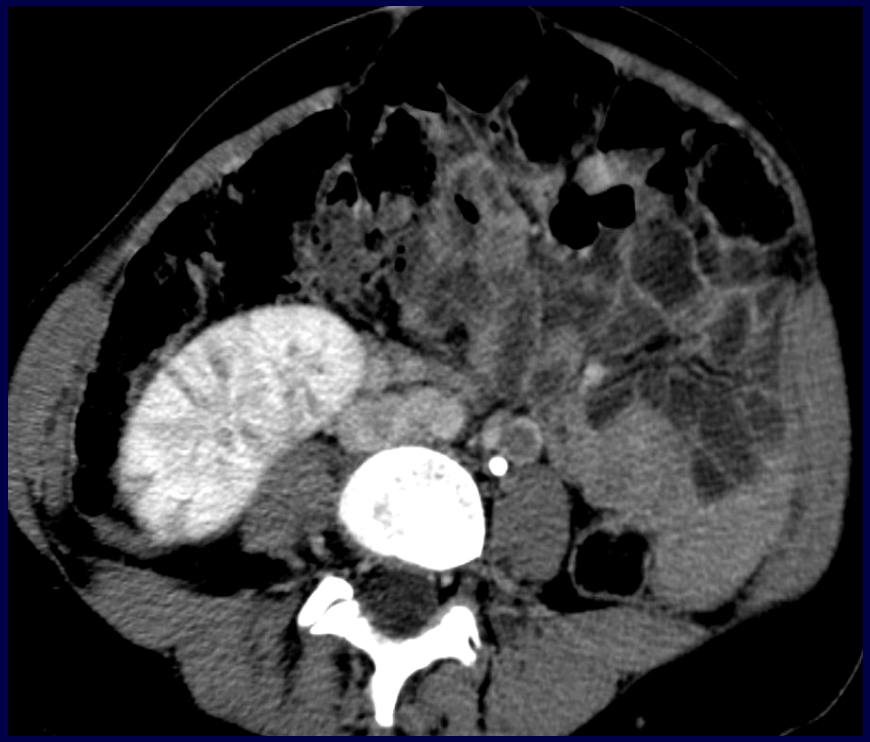

Ovarian vein thrombosis

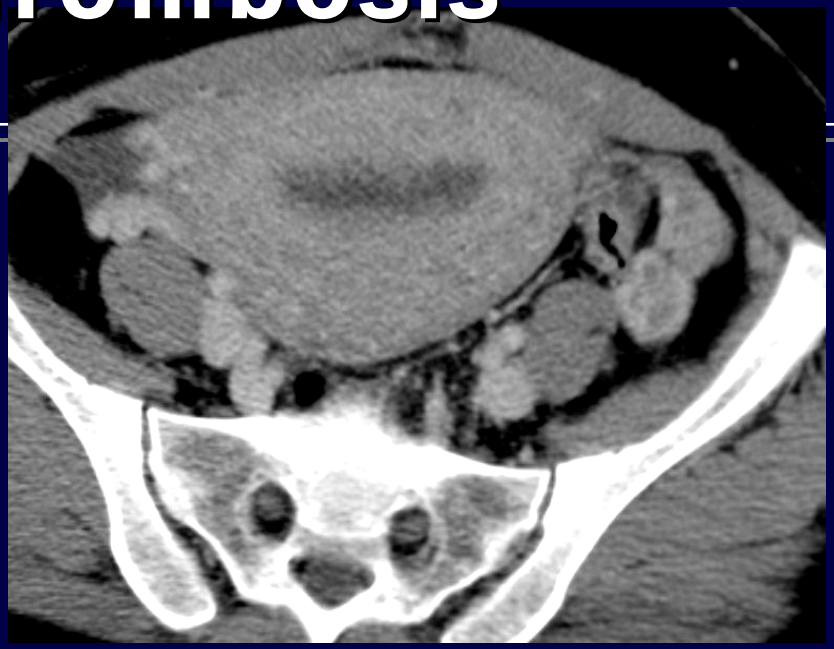

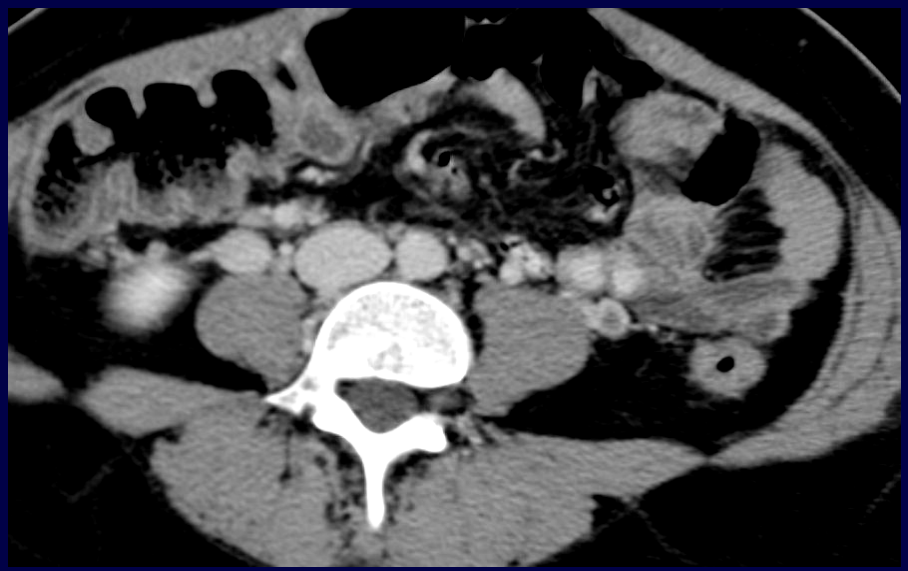

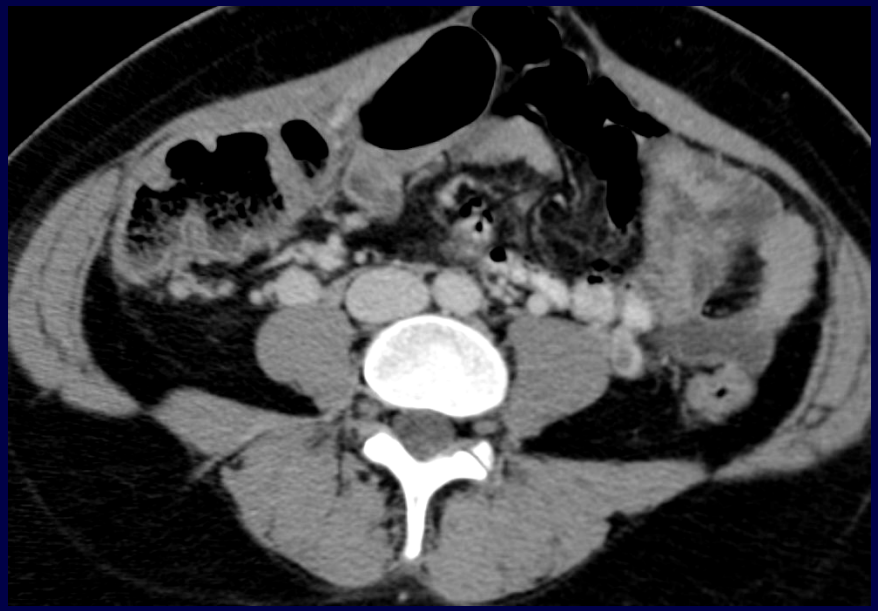

Alternative diagnosis

- Subcapsular liver hematoma complicating pre eclampsia

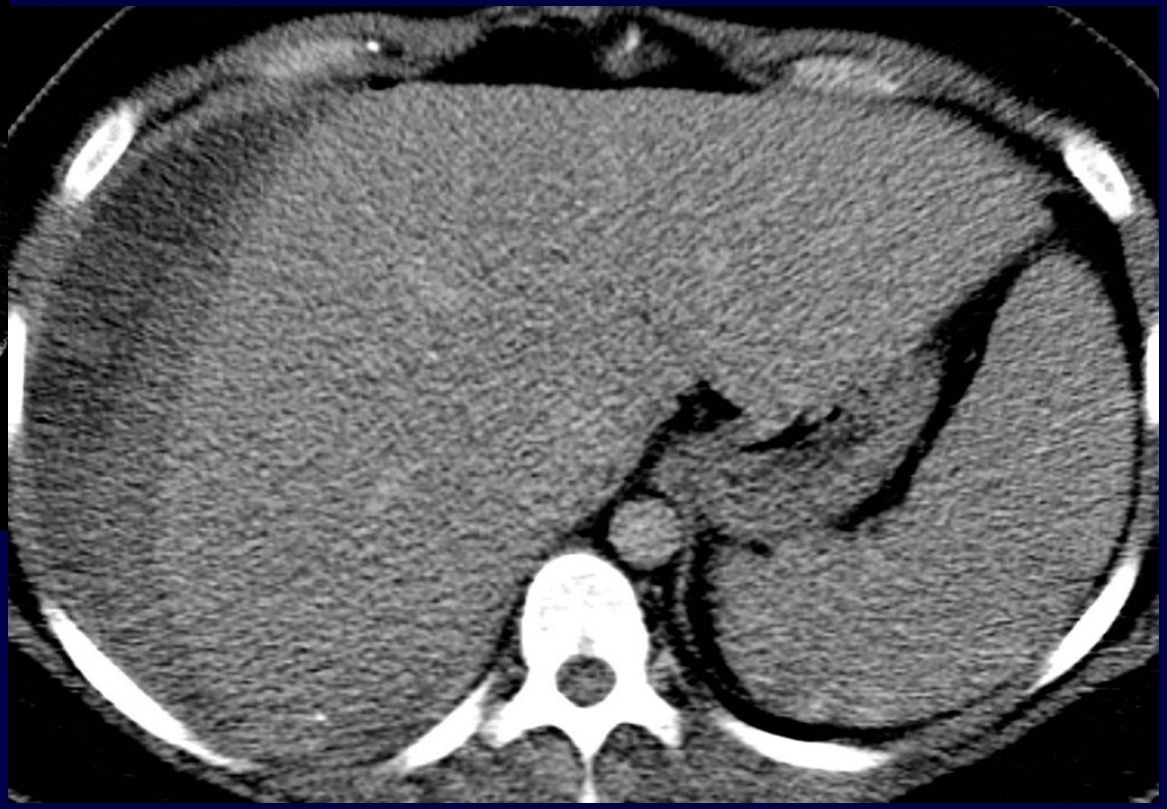

Summary

PE suspicion during pregnancy and post partum

- No specific score, Ddimers not useful
- Chest radiography must be performed
  - Alternative diagnosis? Estimate risk of inconclusive LS
- When CTA performed
  - **Has to be conclusive**
    - no deep breath /at least 100cc@4cc/s /start with a 18 -25 s delay
  - **Low radiation dose**
    - Z axis limitation, noise index increase, bismuth shiedling are good options!

This should be avoided….

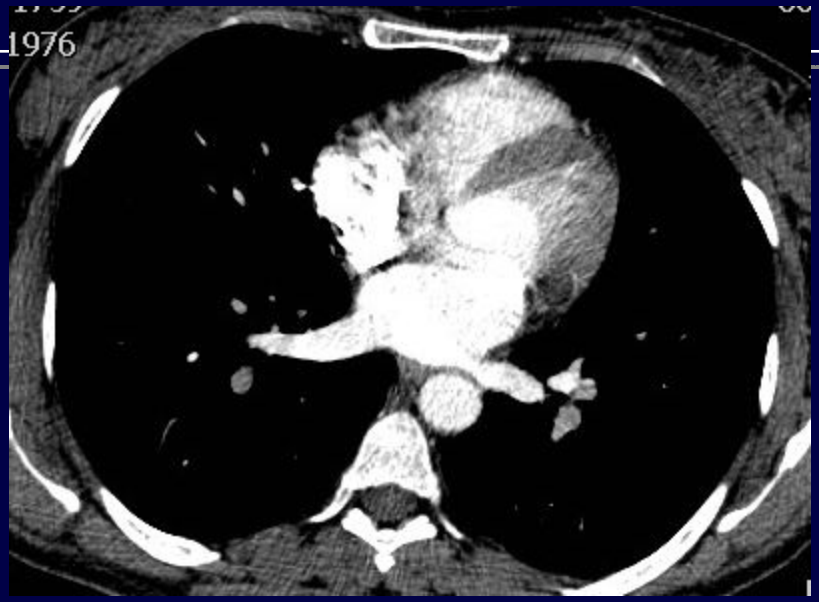

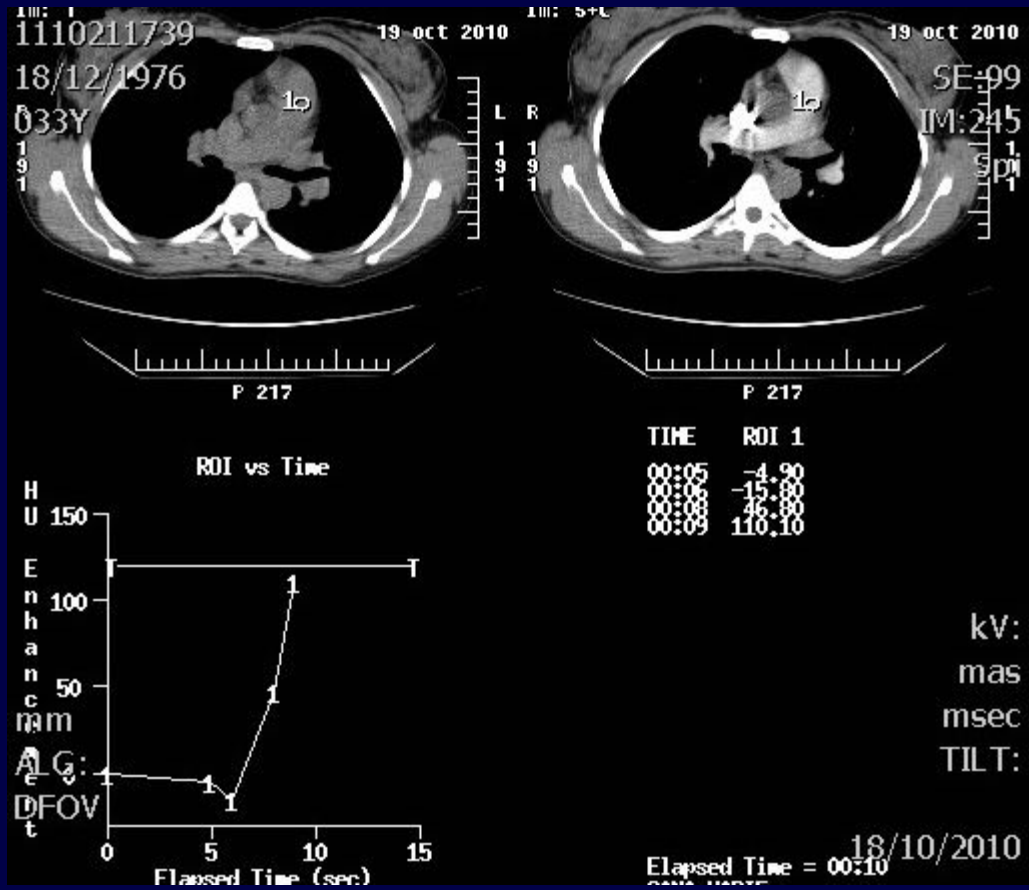

Conclusive CTA with low radiation dose

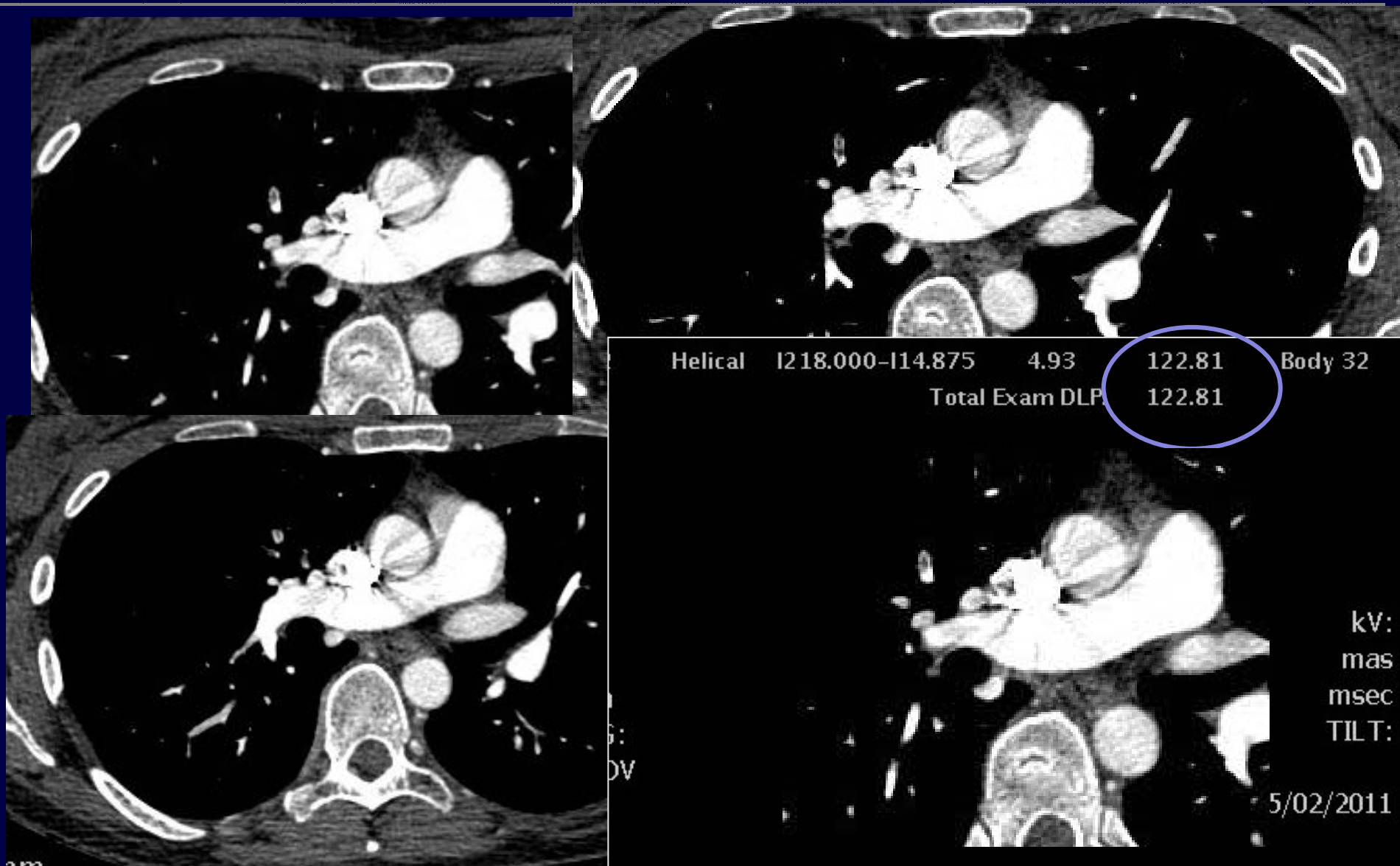


R
I
P
L
S
A

Thank you

Marie-pierre.revel@egp.aphp.fr