



איגוד הרדיולוגים בישראל

Hosting the תארה את

French Radiological Society - SFR

French-Israel Association of Medical Imaging - AFIM

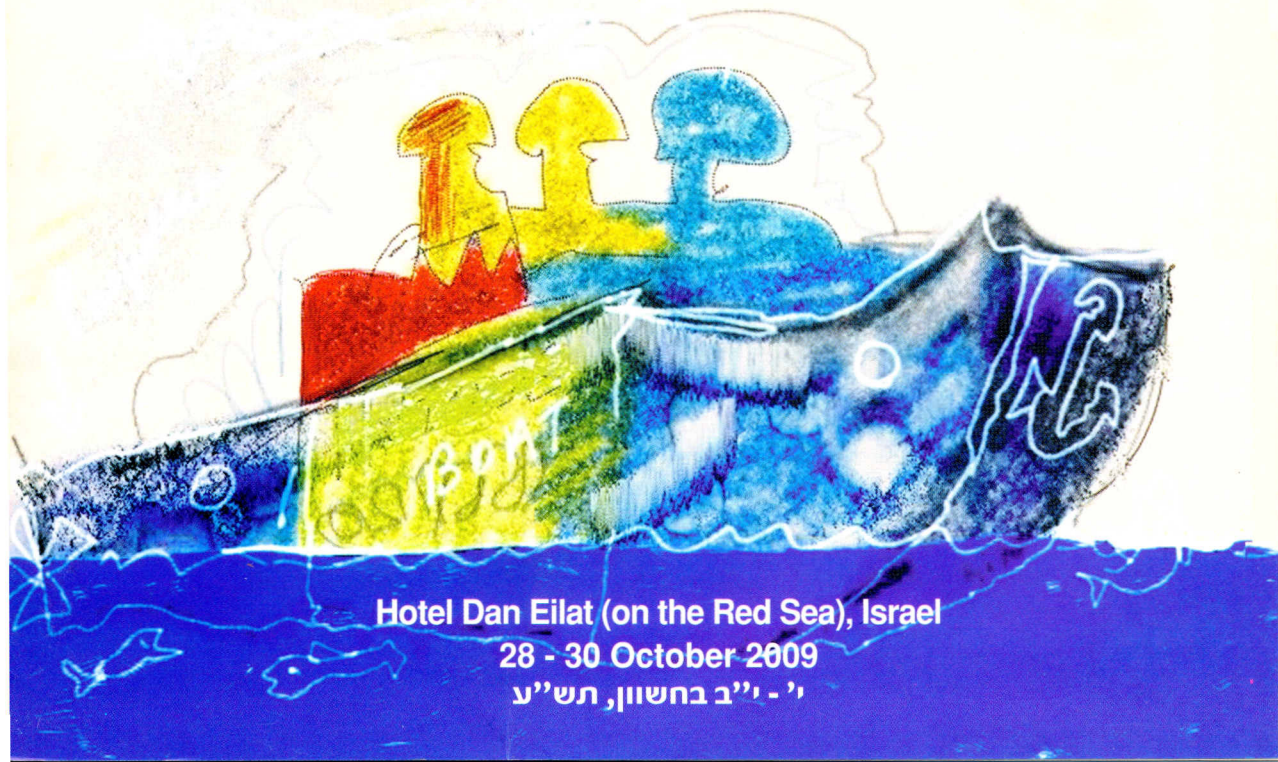

Israel Radiological Association

ISRA - 2009

Annual Meeting

PROGRAM



Hotel Dan Eilat (on the Red Sea), Israel

28 - 30 October 2009

י' - י"ב בחשוון, תש"ע

President of the conference:
Prof. Moshe Graif, *Chairman of ISRA*

Scientific Committee:
**J. Sosna MD (Chairman), R. Zissin MD, A. Blachar MD, E. Konen MD,
A. Engel MD, D. Shaham MD, D. Goldsher MD, N. Peled MD,
G. Bartal MD, L. Kornreich MD**

AFIIM:
Prof. Alain Blum (president), Dr. Henri Azoulay

Coordinators SFR:
Prof. Jean-Denis Laredo, Prof. Alain Chevrot

[ISRA Website:](http://www.israel-radiology.org.il)
www.israel-radiology.org.il



יושב ראש הכנס:
פרופ' משה גרייף, יו"ר איגוד הרדיולוגים

חברי הוועדה המדעית:
**ד"ר י. סוסנה (יו"ר), פרופ' ר. זיסין, ד"ר א. בלשר, ד"ר נ. פלד, ד"ר א. אנגל
ד"ר א. קונן, ד"ר ד. שחם, ד"ר ד. גולדשר, ד"ר ג. ברטל, פרופ' ל. קורנרייך**

החברה הצרפתית-ישראלית לדימות רפואי (AFIIM):
פרופ' אלן בלום (נשיא), ד"ר הנרי אזולאי

נציגי האיגוד הרדיולוגי הצרפתי (SFR):
פרופ' ז'אן-דניס לרדו, פרופ' אלן שברו

[אתר הבית של איגוד הרדיולוגים:](http://www.israel-radiology.org.il)
www.israel-radiology.org.il

Dear colleagues,

We are pleased to forward to you the program for the forthcoming annual conference of the Israel Radiological Association to be held at the "Dan" Hotel, Eilat, Israel, October 28-30, 2009.

As in the past years we will host the members of the Israeli-French Association of Medical Imaging AFIIM and the SFR (AFI).

As in the past we included a pre-conference refresher course on Wednesday October 28, from 12:00-17:00. The refresher course is dedicated to a wide spectrum of topics and is entitled "From Head to Toe".

Our International Annual Guest Lecturers will be Philippe Grenier from France, Michael Federle, Joseph Schoepf and Eithan Halpern from the USA and Jean-Denis Laredo, Marc Zins and Jean-Daniel Piekarski from France.

Among the invited local speakers we would like to mention Moshe Gomori and Dorith Goldsher.

Our Guest of honor for this year is Dr. Hana Manor past chairman of the radiology department at Assaf Harofeh Medical Center.

All lectures, scientific communications and posters will be held in English for the convenience of the international forum of attendees.

As in the past conferences we shall dedicate the "Michal Meidan" award to the best presentation delivered by resident in Radiology.

A case solution quiz will be displayed for all participants and the winner will be awarded.

We continue our traditional collaboration with the Imaging industry Companies. These companies will display, as always, the most recent technological innovations and will be with us throughout all conference days.

Sincerely yours,

Prof. Moshe Graif

President of the meeting

Chairman of the Israel Radiological Association

חברים יקרים,

אנו שמחים ומתכבדים להעביר אליכם את חוברת הכנס השנתי של איגוד הרדיולוגים 2009 שיתקיים בין התאריכים 28-30 באוקטובר, 2009 ימים רביעי-שישי, במלון "דן אילת".

כבשנים קודמות, יחברו אלינו חברי החברה הצרפתית-ישראלית לרדיולוגיה (AFIIM), כאורחינו.

תוכנית הכנס כוללת את קורס הרענון 'קדם כנס' ביום ד' בין השעות 12:00-17:00 הנקרא השנה בשם "מכף רגל ועד ראש" וכולל מניפה רחבה של נושאים.

לכנס השנה הוזמנו מרצים בינלאומיים: הפרופסורים, מייקל פדרלה, יוזף שואפ ואיתן הלפרן מארה"ב והפרופסורים פיליפ גרנייה, ז'אן דניס לרדו, מרק זינס וז'אן דניאל פיקרסקי מצרפת.

לא נפקד מקומם של מרצים חשובים מעולם הרדיולוגיה המקומית כמו פרופ' משה גומורי וד"ר דורית גולדשר.

במהלך הכנס תוצגנה קרוב למאה עבודות מדעיות מקומיות מקוריות.

אורחת הכבוד של הכנס השנה תהיה ד"ר חנה מנור על תרומתה רבת השנים להוראת סטודנטים, גידול זוחות רדיולוגים והדרכת קלינאים - כל זאת באהבה רבה ובסבלנות אין קץ.

כן נקיים בכנס את המסורות שהונהגו בו בעבר והכוללות הענקת הפרס ע"ש מיכל מידן ז"ל עבור עבודת המחקר המצטיינת למתמחה. פרס נוסף ינתן לפותר החידון הרדיולוגי בכנס.

זו ההזדמנות להודות לנציגי התעשייה המשתתפים באופן מסורתי, לאורך כל השנים, ולחברות החדשות המצטרפות התומכות בכנס זה של האיגוד, אשר יציגו את החידושים האחרונים בתחום הדימות הרפואי.

בברכת שנה טובה,

ואיחולים להצלחה והנאה לכולכם באילת

פרופ' משה גרייף

נשיא הכינוס

יו"ר איגוד הרדיולוגים בישראל

Program at a Glance

Wednesday 28.10.2009		Thursday 29.10.2009		Friday 30.10.2009			
Hall A		Hall A	Hall B	Hall A	Hall B		
10:00-12:00	<i>Registration</i>	09:00-09:20	Opening Remarks: M. Graif MD Chairman of ISRA		09:00-09:20	Guest Lecturer: E.J. Halpern, MD (USA)	
		09:20-09:50	Guest Lecturer: M.P. Federle, MD (USA)		09:20-10:30	Session 8: Cardiovascular Imaging - Part 2	Session 9: General and Musculoskeletal Imaging
		09:54-10:30	Session 1: Abdominal Imaging - part 1				
		10:30-11:00	Coffee Break		10:30-11:00	Coffee Break	
		11:00-11:30	Guest Lecturer: P. Genier, MD (France)		11:00-11:30	Guest Lecturer: M. Zins, MD (France)	
		11:30-12:00	Guest Lecturer: J.U. Schoepf, MD (USA)		11:00-12:45	Session 10: Abdominal Imaging - Part 3	Session 11: Interventional Radiology
12:00-13:30	Refresher and Educational Course: Radiology Review from "Head to Toe"	12:00-13:30	Session 2: Cardiovascular Imaging - Part 1	Session 3: Abdominal Imaging - Part 2	12:45-13:15	QUIZ SOLUTION Michal Meidan Award Closing Remarks	
13:30-14:30		Lunch Break and Professional Meeting for members only		13:15-14:30		Light Lunch	
13:30-14:00	Light Lunch Break						
14:00-15:30	Refresher and Educational Course: Radiology Review from "Head to Toe"	14:30-15:30	Session 4: Chest Imaging	Session 5: Pediatric Imaging			
15:30-16:00	Coffee Break	15:30-16:00	Coffee Break				
16:00-17:00	Refresher and Educational Course: Radiology Review from "Head to Toe"	16:00-16:20	Guest Lecturer: J.M. Gomori, MD (IL)				
17:00-19:00		16:20-17:00	Session 6: Neuroradiology	Session 7: Breast Imaging			
17:00-19:00	Satellite Symposium AFIM						
19:30-22:00	WELCOME COCKTAIL RECEPTION	20:00	GALA DINNER				

ISRA 2009 Conference Program

Refresher and Educational Course: Radiology Review from "Head to Toe"

Hall A

Wednesday, October 28, 2009

10:00-12:00 **Registration**

12:00-12:30 White matter disease
D. Goldsher, Haifa, Israel

12:30-13:00 Neck tumors
J.D. Piekarski, Paris, France

13:00-13:30 Management of a small pulmonary nodule
P. Grenier, Paris, France

13:30-14:00 **Light Lunch Break**

14:00-14:30 Cardiac CTA: Common indications and findings
J.U. Schoepf, Charleston, SC, USA

14:30-15:00 Focal hepatic masses in cirrhotic livers
M.P. Federle, Stanford, CA, USA

15:00-15:30 Focal hepatic masses in non- cirrhotic livers
M.P. Federle, Stanford, CA, USA

15:30 -16:00 **Coffee Break**

16:00-16:30 Vertebral pseudo-tumors and diagnosis of non-traumatic vertebral collapse
J.D. Laredo, Paris, France

16:30-17:00 Tips and tricks on how to improve your abstract
J. Sosna, Jerusalem, Israel

17:00-19:00 **Satellite Symposium - AFIIM**

**Carvical and transcranial doppler - Workshop From Theory to Practice
Hands-On Training**
J-C Sadik, Paris France

19:30-22:00 **Welcome Cocktail Reception**

Thursday October 29, 2009

- 08:00-09:00 Registration
- 09:00-09:20 Opening Remarks - **M. Graif MD**, Chairman of ISRA **Hall A**
- 09:20-09:50 Making Sense of Pancreatic Tumors
Guest Lecturer: M.P. Federle MD, (USA)
- 09:54-10:30 **Session 1: Abdominal Imaging - Part 1** **Hall A**
Plenary Session
- 09:54-10:03 Dropped gallstones following laparoscopic cholecystectomy revealed on CT - Appearance and incidence of complications
Gayer G.
Stanford Medical Center, Stanford, California, USA
- 10:03-10:12 Intraluminal bowel opacification on CT following oral ingestion of Kayexalate (sodium polystyrene sulphonate)
Zissin R., Stackievich R., Osadchy A., Gayer G.
Meir Medical Center, Kfar Saba, Israel
- 10:12-10:21 Acute massive gastrointestinal bleeding: Role of CT angiography at The Tel-Aviv Sourasky Medical Center
Adam S.Z., Mercer D., Blachar A.
Sourasky Medical Center, Tel-Aviv
- 10:21-10:30 Radiologist performance in the diagnosis of intestinal ischemia, using MDCT and specific CT findings in a setup simulating routine practice
Barnes S., Adam S.Z., Levi G., Vienshtien Y., Pretzel R., Sosna J., Blachar A.
Sourasky Medical Center, Tel-Aviv
- 10:30-11:00 **Coffee Break**
- 11:00-11:30 Smokers' Lung
Guest Lecturer: P.Grenier MD (France)
- 11:30-12:00 Evidence Based Coronary CTA-in 2009
Guest Lecturer: Joseph U. Schoepf MD, (USA)
- 12:00-13:30 **Session 2: Cardiovascular Imaging - Part 1** **Hall A**
Parallel Session
- 12:00-12:09 Adenosine stress dual-energy CT of the heart for diagnosing myocardial ischemia and viability compared with cardiac MRI and SPECT
Abro J.A., Charleston M.A., Ruzsics B., Arnoldi E.M., Zwerner P., Chiamida S., Schoepf U.J.
Medical University of South Carolina, USA
- 12:09-12:18 Evaluation of the coronary arteries as part of routine scanning using a new fast-gated protocol on a 256-slice scanner
Gaspar T., Sachner R., Khashper A., Shnapp M., Domachevsky L., Peled N.
Lady Davis Carmel Medical Center, Haifa
- 12:18-12:27 Automated computer aided stenosis detection on coronary CT angiography - Initial experience
Arnoldi E.M., Thilo C., Gebregziabher M., Ramos-Duran L., Zwerner P.L., Goldenberg R., Reiser M.F., Schoepf J.U., Abro J.A.
Medical University of South Carolina, USA

- 12:27-12:36 Can benefit be expected from further risk factor modification in treated diabetics with pre-clinical coronary artery disease? A 64 slice coronary CT angiography study
Gaspar T., Dobrecky-Mery I., Sachner R., Yaniv N., Davidov V., Halon D.A., Peled N.
Lady Davis Carmel Medical Center, Haifa
- 12:36-12:45 Step-And-Shoot, a new low radiation coronary computed tomography angiography technology: Our initial experience in 125 consecutive asymptomatic patients
Atar E., Kornowski R., Bachar N.G
Rabin Medical Center, Petach-Tikva
- 12:45-12:54 UKPDS coronary heart disease risk score correlates with extent and type of plaque in asymptomatic type 2 diabetics: A study using 64 slice coronary CT angiography
Gaspar T., Sachner R., Halon D.A., Dobrecky-Mery I., Peled N.
Lady Davis Carmel Medical Center, Haifa
- 12:54-13:03 Correlation between ear lobe crease and coronary artery disease as assessed by coronary CT angiography
Eshet Y., Goitein O., Matetzky S., Di Segni E., Hamdan A., Konen E.
Chaim Sheba Medical Center, Israel
- 13:03-13:12 Prospectively gated coronary CT - "Step and shoot" in the chest pain unit: Markedly reduced radiation exposure with diagnostically acceptable quality
Goitein O., Beigel R., Matetzky S., Kuperstein R., Eshet Y., DiSegni E., Konen E.
Chaim Sheba Medical Center, Israel
- 13:12-13:21 Can dual-energy CT of the heart acquired at rest detect reversible ischemia seen on stress myocardial perfusion imaging?
Abro J.A., Charleston M.A., Ruzsics B., Schwarz F., Lee Y., Bastarrika G., Zwerner P., Schoepf U.J.
Medical University of South Carolina, USA
- 13:21-13:30 Does obstructive coronary plaque have different composition to non-obstructive plaque? A study using 64-Slice cardiac CTA in asymptomatic Type 2 diabetics
Halon D.A., Gaspar T., Sachner R., Dobrecky-Mery I., Peled N.
Lady Davis Carmel Medical Center, Haifa

12:00-13:30 **Session 3: Abdominal Imaging - Part 2**
Parallel Session

Hall B

- 12:00-12:09 Endorectal prostate MRI for patients with elevated PSA and negative biopsies - An emerging indication
Ben David E., Pode D., Ariely J., Sella T.
Hadassah Medical Center, Jerusalem, Israel
- 12:09-12:18 The relationship between stone characteristics and secondary signs for renal colic
Berkovitz N., Katz R., Simanovsky N., Hiller N.
Hadassah Medical Center, Jerusalem, Israel
- 12:18-12:27 CT guided percutaneous core-biopsy of renal masses: Short-term complications and risk factors, a prospective study
Berkovitz N., Zisman A., Lindner A., Raz O., Gotlieb P., Copel L.
Hadassah Medical Center, Jerusalem, Israel
- 12:27-12:36 CT guided percutaneous core-biopsy of renal masses: Impact on clinical management, a prospective study
Copel L., Berkovitz N., Lindner A., Sandbank J., Raz O., Gotlieb P., Zisman A.
Assaf-Harofeh Medical Center, Zerifin, Israel

- 12:36-12:45 Optimizing organ measurement- an example of evaluating the kidney length in an abdominal CT
Cytter-Kuint R., Hadas-Halpern I., Bar Ziv J.
Shaare Zedek Medical Center, Jerusalem, Israel
- 12:45-12:54 Prediction of long-term success rates of MRgFUS for uterine fibroids
Inbar Y., Chaitovich B., Machtinger R., Admon D., Cohen-Eylon S., Rabinovici J.
Chaim Sheba Medical Center, Israel
- 12:54-13:03 Non-Contrast Computerized Tomography (NCCT) and Dynamic Renal Scintigraphy (DRS) in patients with refractory renal colic
Lebedev V., Kravchick S., Mamonov A., Linov L.
Barzilai Medical Center, Ashkelon, Israel
- 13:03-13:12 MDCT urography – Evolution of a protocol
Portnoy O., Guranda L., Konen E., Amitai M., Apter S.
Chaim Sheba Medical Center, Israel
- 13:12-13:21 Normal CT appearance of the pelvis after Cesarean section
Schor Bardach R., Stromza D., Simanovsky N., Hiller N.
Hadassah Medical Center, Jerusalem, Israel
- 13:21-13:30 CT findings after partial laparoscopic nephrectomy with use of surgical
Wandel A., Tsivian A., Bartal G., Elias S., Sidi A.
Meir Medical Center, Kfar Saba, Israel
- 13:30-14:30 **Lunch Break and Professional Meeting for members only**
- 14:30-15:30 **Session 4: Chest Imaging** **Hall A**
Parallel Session
- 14:30-14:39 Lung radiofrequency ablation: 3 year experience in a single Israeli institution
Appelbaum L., Goldberg S.N., Sosna J., Libson E., Izhar U.
Hadassah Medical Center, Jerusalem, Israel
- 14:39-14:48 Reduced left atrial area with increased clot load in patients with acute pulmonary embolism
Aviram G., Steinvil A., Berliner S., Rosen G., Sosna J., Man A., Keren G., Rogowski O.
Sourasky Medical Center, Tel-Aviv
- 14:48-14:57 Can CAD detect sub-solid lung nodules on digital chest radiographs?
Shaham D., Bogot N.R., Lederman R., Manevitch A., Merlet N., Abramov M. Belhdeb M Leichter I.
Hadassah Medical Center, Jerusalem, Israel
- 14:57-15:06 CT appearance of pulmonary amyloidosis
Caluti S.
Shaare Zedek Medical Center, Jerusalem, Israel
- 15:06-15:15 Imaging findings of aspirated endobronchial foreign bodies in adults: Report of 26 patients
Osadchy A., Zissin R.
Meir Medical Center, Kfar Saba, Israel
- 15:15-15:24 CT Guided Lung Biopsies Using a Novel Optical Navigation System: Initial Human Experience
Aviram G., Schwarz Y., Man A., Tiran B., Rosen G., Sosna J.
Sourasky Medical Center, Tel-Aviv
- 15:24-15:33 Bronchogenic carcinoma in young adults without known risk factors
Yagil Y., Engel A., Wollner M., Guralnik L.
Rambam Medical Center, Haifa, Israel

14:30-15:30 **Session 5: Pediatric Imaging**
Parallel Session

Hall B

- 14:30-14:39 The Added value of ECG gated CT for complex congenital heart disease in children
Goitein O., Jacobson J., Katz U., Eshet Y., Vardi A., Hamdan A., Mishali D., Danieli J., Di Segni E., Konen E.
Chaim Sheba Medical Center, Israel
- 14:39-14:48 Air encircling the intussusceptum on air enema for intussusception reduction: A sign that surgery is indicated
Koplewitz B.Z., Simanovsky N., Lebensart P.D., Udassin R., Abu-Dalu K., Arbell D.
Hadassah Medical Center, Jerusalem, Israel
- 14:48-14:57 Orbital cellulitis in children: Beyond subperiosteal abscess
Kornreich L., Friling R., Hasanreisoglu M., Yassur I., Amir J. Libni G., Garty B.Z., Snir M.
Schneider's Children Medical Center, Petach Tikva, Israel
- 14:57-15:06 Fetal body MRI - Comparison to prenatal ultrasound and postnatal findings: 5 years experience at the Sheba Medical Center
Raviv-Zilka L., Ben-Shlush A., Jacobson J., Berkenstadt M., Soudack M.
Chaim Sheba Medical Center, Israel
- 15:06-15:15 Spondylo-meta-epiphyseal dysplasia, short limb-abnormal calcification type: The changing radiological findings
Rozovsky K., Rotshild A., Sosna J.
Hadassah Medical Center, Jerusalem, Israel
- 15:15-15:24 Magnetic Resonance Imaging Findings in West Syndrome
Konen O., Cohen R., Kornreich L., Shuper A.
Schneider's Children Medical Center, Petach Tikva, Israel
- 15:24-15:33 Exertional leg pain in FMF patients evaluated by MRI of the ankle and MR spectroscopy of the thigh
Eshed I., Kushnir T., Livneh A., Lidar M.
Chaim Sheba Medical Center, Israel

15:33-16:00 **Coffee Break**

- 16:00-16:20 CTA for Brain Death Evaluation
Guest Lecturer: J.M. Gomori MD (Israel)

16:20- 17:30 **Session 6: Neuroradiology**
Parallel Session

Hall A

- 16:20-16:29 CAD detection of brain pathology
Bar-Meir E., Graif M., Blinder J., Zaaroor M., Eran A., Gomori M.
Bnai zion medical center, Haifa, Israel
- 16:29-16:38 Diffusion MRI findings in monozygotic twin pregnancies after selective reduction by bipolar coagulation of the cord
Hoffman C., Weisz B., Greenberg G., Gindes L., Chayen B., Achiron R. Lipitz S.
Chaim Sheba Medical Center, Israel
- 16:38-16:47 Magnetic Resonance Spectroscopy in Amnesic Mild Cognitive Impairment and Alzheimer Disease
Inspector M., Nemirovsky A., Aharon-Perez J., Gilboa A., Goldsher D.
Rambam Health Care Campus, Haifa, Israel

- 16:47-16:56 Intracranial non-jugular venous pathways: A possible compensatory drainage mechanism
Shelef I., Kopelman M., Glik A., Grinberg S.
Soroka Medical Center and Ben-Gurion University, Israel
- 16:56-17:05 Diffusion tensor imaging reveals the structure of giant brain lesions in multiple sclerosis
Tal S., Miron S., Achiron A.
Chaim Sheba Medical Center, Israel
- 17:05-17:14 Diffusion tensor imaging of corpus callosum integrity in multiple sclerosis: Correlation with disease variables
Tal S.
Chaim Sheba Medical Center, Israel
- 17:14-17:23 Abnormal olfactory function demonstrated by manganese enhanced MRI (MEMRI) in mice with experimental neuropsychiatric lupus (NPSLE)
Tsarfaty G., Kivity S., Agmon-Levin N., Blank M., Manor D., Konen E., Chapman J., Reichlin M., Shoenfeld Y., Kushnir T.
Chaim Sheba Medical Center, Israel

16:20-17:50 **Session 7: Breast Imaging**
Parallel Session

Hall B

- 16:20-16:29 A New guidance device for lateral-approach stereotactic breast biopsy
Kornecki A., Ma K., Bax J., Mundt Y., Fenster A.
St. Joseph Health Care, University of Western Ontario, Canada
- 16:29-16:38 An Algorithmic approach to breast MR imaging screen detected lesions in high-risk women
Arzi-Kleinman T., Causer P., Warner E., Plewes D., Hill K., Jong R.
Sourasky Medical Center, Tel-Aviv, Israel
- 16:38-16:47 Is CAD performance in mammography affected by breast density, lesion pathology or lesion size?
Gallimidi Z., Lederman R., Heyman-Reiss A., Merlet N., Ratner E., Abramov M., Stainvas I., Leichter I.
Rambam Health Care Campus, Haifa, Israel
- 16:47-16:56 Prevalence and location of intramammary lymph nodes on breast MRI
Arzi-Kleinman T., Sperber F.
Sourasky Medical Center, Tel-Aviv, Israel
- 16:56-17:05 Diagnostic accuracy of MRI, compared to mammography and ultrasound, in preoperative assessment of women younger than 40 years old with breast cancer
Golan O., Sperber F., Schneebaum S., Barsuk D.
Sourasky Medical Center, Tel-Aviv, Israel
- 17:05-17:14 Sniffing out breast cancer from real breath samples by means of nanomaterial-based electronic nose device
Gallimidi Z., Heyman Reiss A., Engel A., Shuster G., Dvorkind I., Haick H.
Rambam Health Care Campus, Haifa, Israel
- 17:14-17:23 Breast MRI artifact on axial imaging - Analysis and solution
Sella T., Azraq Y., Fisch S., Arzi Kleinman T., Gomori J.M.
Hadassah Medical Center, Jerusalem, Israel
- 17:23-17:32 Atypical breast MRI presentation of ruptured silicone implants
Sperber F., Barnea Y.
Sourasky Medical Center, Tel-Aviv, Israel

- 17:32-17:41 Diffusion MRI tracking the mammary ductal trees in vivo: A novel method for breast cancer detection
Eyal E., Shapiro Feinberg M., Furman-Haran E., Grobgeld D., Golan T., Sklair-Levi M., Catane R., Papa M., Degani H.
Meir Medical Center, Kfar Saba, Israel
- 17:41-17:50 MR appearance of fibroadenomas - imaging characteristics with pathologic correlation
Sella T., Arazi Kleinman T., Azraq Y., Maly B.
Hadassah Medical Center, Jerusalem, Israel

20:00 **Gala Dinner**

Friday October 30, 2009

- | | | |
|-------------|--|---------------|
| 09:00-09:20 | Triple Rule Out CT
<u>Guest Lecturer:</u> E.J. Halpern MD (USA) | Hall A |
| 09:20-10:30 | Session 8: Cardiacvascular Imaging - Part 2
Parallel Session | Hall A |
| 09:20-09:40 | Choosing between CCTA and Nuclear Test
<u>Guest Lecturer:</u> E.J. Halpern MD (USA) | |
| 09:40-09:49 | Anatomic and hemodynamic MRI Characteristics of Partial Anomalous Pulmonary Venous Return (PAPVR) with or without Sinus Venosus Defect (SVD) in a sequential series of patients
Konen E., Goitein O., Kuperstein R., Merchant N., Eshet Y., Di-Segni E.
<i>Chaim Sheba Medical Center, Israel</i> | |
| 09:49-09:58 | Visceral fat predicts coronary atherosclerosis independently from the metabolic syndrome in asymptomatic diabetic patients - a 64 slice CT study
Khashper A., Peysakhovich T., Gaspar T., Dobrecky-Mery I., Sachner R., Halon D.A., Peled N.
<i>Lady Davis Carmel Medical Center, Haifa</i> | |
| 09:58-10:06 | Statin therapy and coronary plaque characteristics on 64 slice cardiac CT in asymptomatic type 2 diabetics
Halon D.A., Gaspar T., Sachner R., Dobrecky-Mery I., Yaniv N., Peled N.
<i>Lady Davis Carmel Medical Center, Haifa</i> | |
| 10:06-10:15 | The vulnerable atherosclerotic plaque: Enhanced characterization with macrophage specific iodinated nanoparticles and dual energy MDCT
Sosna J., Kafri G., Goshen L., Carmi R., Planer D.
<i>Hadassah Medical Center, Jerusalem, Israel</i> | |
| 10:15-10:24 | Heart rate recovery immediately after exercise is a predictor of pre-clinical coronary atheroma in asymptomatic type 2 diabetics
Dobrecky-Mery I., Sachner R., Gaspar T., Domachevsky L., Peysakhovich T., Halon D.A., Peled N.
<i>Lady Davis Carmel Medical Center, Haifa</i> | |
| 10:24-10:33 | Metabolic syndrome, intra-thoracic fat and coronary artery atherosclerosis in asymptomatic diabetic patients - a 64 slice CT study
Khashper A., Peysakhovich T., Gaspar T., Dobrecky-Mery I., Sachner R., Halon D.A., Peled N.
<i>Lady Davis Carmel Medical Center, Haifa</i> | |

09:30-10:30 **Session 9: General and Musculoskeletal Imaging**
Parallel Session

Hall B

- 09:30-09:39 Generation of an X-RAY teaching file directly from an electronic health record
Fields S., Kovalski N.
Diagnostic Imaging Ltd.
- 09:39-09:48 Digital radiography image intensity changes induced by temperature
Hirschenbein A., Gomori J.M., Sosna J.
Hadassah Medical Center, Jerusalem, Israel
- 09:48-09:57 The effects of adding a patient's photograph to the radiographic examination
Turner Y.N., Hadas-Halpern I., Silberman S., Sandor J.
Share Zedek Medical Center, Jerusalem
- 09:57-10:06 Implementation of an organizational PACS in the Clalit Health Services
Makori A.
Clalit Health Services
- 10:06-10:15 MDCT intensity changes induced by temperature: Phantom analysis
Hirschenbein A., Gomori J.M., Sosna J.
Hadassah Medical Center, Jerusalem, Israel
- 10:15-10:24 Prefemoral fat pad edema on MRI of the knee
Shabshin N., Thein R., Dipremiro G., Schweitzer M.
Chaim Sheba Medical Center, Israel
- 10:24-10:35 Thyroid ultrasonography - Malignancy sonographic signs with FNA and pathological correlation
Aizikovich S., Linov L., Halperin I., Bendor D., Gheorghiu D., London D.
Barzilai Medical Center, Ashkelon
- 10:35-10:44 H syndrome - spectrum of radiological findings in a newly discovered inherited disorder
Hiller N., Molho-Pessach V., Simanovsky N., Zlotogorski A.
Hadassah Medical Center, Jerusalem, Israel

10:30-11:00 **Coffee Break**

- 11:00-11:30 Small Bowel Obstruction
Guest Lecturer: M.Zins MD (France)

11:30-12:33 **Session 10: Abdominal Imaging - Part 3**
Parallel Session

Hall A

- 11:30-11:39 Abdominal MR imaging of pregnant women for non fetal indications
Amitai M., Stern M., Inbar Y., Itzchak Y., Hertz M., Apter S.
Chaim Sheba Medical Center, Israel
- 11:39-11:48 Baseline visceral to subcutaneous fat ratio at MDCT predicts the metabolic response to bariatric surgery
Appelbaum L., Sosna J., Weiss R., Keidar A.
Hadassah Medical Center, Jerusalem, Israel
- 11:48-11:57 Small bowel diverticulitis: CT findings in 13 cases
Ben Artzi M., Osadchy A., Zissin R.
Meir Medical Center, Kfar Saba, Israel
- 11:57-12:06 Early and late graft pseudoaneurysms following pancreatic transplantation
Kessler A., Lubetzki N., Rosen G., Kori I., Nakash R., Ben-Haim M.
Sourasky Medical Center, Tel-Aviv, Israel

- 12:06-12:15 Preoperative planning of deep inferior epigastric artery perforator flap breast reconstruction using computed tomography - CTA
Ronen G., Barnea Y., Blachar A.
Sourasky Medical Center, Tel-Aviv, Israel
- 12:15-12:24 Min- cut method for liver vessel segmentation from MDCT: Algorithm assessment and verification
Sosna J., Lev-Cohen N., Natanzon M., Broide N., Freiman M., Joskowicz L.
Hadassah Medical Center, Jerusalem, Israel
- 12:24-12:33 Endoanal ultrasound combined with perineal ultrasound in perianal inflammation: Does it improve the diagnostic yield? Preliminary experience
Webb M., Santo E., Ron Y., Halperin Z.
Sourasky Medical Center, Tel-Aviv, Israel

11:30-12:45 **Session 11: Interventional Radiology
Parallel Session**

Hall B


- 11:30-11:39 The use of stent grafts in complicated arteriovenous access false aneurysms
Shemesh D., Goldin I., Zaghal I., Berlowitz D., Verstandig A., Olsha O.
Share Zedek Medical Center, Jerusalem
- 11:39-11:48 How to buy your new digital angiography x-ray system :Tailoring the choice to the real needs of the interventional radiologist
Bartal G., Vano E., Fernandez-Soto J.M., Desponds L., Hoornaert B., Geiger B., Sapoval M.
Meir Medical Center, Kfar Saba, Israel
- 11:48-11:57 TIPS creation for the treatment of portomesenteric thrombosis (isolated or secondary to Budd Chiari syndrome) in 6 patients
Kori I., Rosen G., Samuels D., Ben-Haim M
Sourasky Medical Center, Tel-Aviv, Israel
- 11:57-12:06 A sheathless technique of central venous catheter insertion:
A six years experience
Papura S., Singer-Jordan J.
Western Galilee Hospital Naharyia
- 12:06-12:15 Proximal embolization for traumatic splenic injury : The clinical concept and technical considerations
Rosen G., Kori I., Samuels D., Kessler A., Zmora O., Sofer D.
Sourasky Medical Center, Tel-Aviv, Israel
- 12:15-12:24 Percutaneous insertion of metal endoprostheses for the palliation of malignant biliary obstruction
Yilmaz M., Klimov A., Bloom A.I.,
Hadassah Medical Center, Jerusalem, Israel
- 12:24-12:33 Angioplasty with the Gore Hemobahn and Viabahn stent-grafts in arteriovenous access for hemodialysis
Shemesh D., Goldin I., Zaghal I., Berlowitz D., Verstandig A., Olsha O.
Share Zedek Medical Center, Jerusalem
- 12:33-12:42 Retrospective comparison of mechanical percutaneous thrombectomy with the "lyse and wait" technique for declotting thrombosed hemodialysis arteriovenous grafts
Atar E., Vashchenko N., Bachar G.N., Neiman C., Ori Y., Belenky A., Korzets A.
Rabin Medical Center, Petach Tikva
- 12:40-13:15 Michal Meidan Award Ceremony, Quiz Solutions and awards, Closing Remarks

12:15 - 13:45 **Light Lunch**

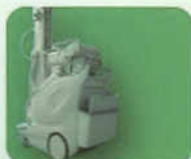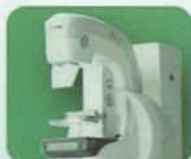DINCO L.T.D

דינקו בע"מ

Dinco Ltd - Imaging since 1973
Medical, Scientific, Industrial and veterinary Solutions



FUJIFILM



SYNAPSE™
PACS solution



DINCO L.T.D



SHIMADZU



www.dinco.co.il

EXHIBITORS:

Bayer-Schering Pharma

CarestreamHealth - Kodak - Digital Medical Systems (DMS)

CMT Medical Technologies

Eldan Electronic Instruments Co. Ltd.

Elsmor

Dexxon Ltd.

GE Healthcare

McKesson

Neopharm

Philips Medical Systems Israel

Siemens Medical Solutions Israel

Sci-lab

Teva Medical



82 Derech Menachem Begin, Tel Aviv 67138, Israel
Tel: 972-3-7610802/7, Fax: 972-3-7610799